Surgical Outcomes and Predictors of Stroke in a North American White and African American Moyamoya Population

Grant W. Mallory, MD*
Regina S. Bower, MD*
Macaulay E. Nwojo, MD*
Philipp Taussky, MD‡
Nicholas M. Wetjen, MD*
Thais C. Varzoni, MD‡
Ricardo A. Hanel, MD‡
Fredric B. Meyer, MD*

*Department of Neurosurgery, Mayo Clinic Rochester, Rochester, Minnesota; ‡Department of Neurosurgery, Mayo Clinic Florida, Jacksonville, Florida

Correspondence:
Fredric B. Meyer, MD,
Department of Neurosurgery,
Mayo Clinic Rochester,
200 First St SW,
Rochester, MN 55902.
E-mail: meyer.fredric@mayo.edu

Received, March 6, 2013.
Accepted, September 4, 2013.
Published Online, September 11, 2013.

Copyright © 2013 by the
Congress of Neurological Surgeons

BACKGROUND: The majority of moyamoya surgical series have been confined to Asian and pediatric populations. Few have studied demographics, risk factors, and outcomes in adult North American populations.

OBJECTIVE: To examine outcomes after revascularization for moyamoya in white and African American adults and to assess for predictors of recurrent stroke.

METHODS: A retrospective review of 75 non-Asian patients undergoing 110 procedures at the Mayo Clinic was performed. Demographics, known moyamoya associations, cerebrovascular risk factors, and autoimmune diseases were recorded. Primary outcomes for vascular events were assessed with Kaplan-Meier analysis. Fisher exact methods were used to evaluate for associations with recurrent events.

RESULTS: Mean age was 42 years, and mean follow-up was 47 months. Seventy-one of the 75 patients were white. The majority had bilateral disease (n = 49). Perioperative ischemic events occurred in 5 patients (4.5%). The 5- and 10-year event rates were 5.8% and 9.9%. Significant associations were found with a history of thyroid disease ($P = .05$) and recurrent stroke. A trend was also found between hypertension and autoimmune disease with recurrent stroke.

CONCLUSION: Outcomes were favorable with revascularization in this subset with moyamoya. A significant association between a history of thyroid disease and recurrent stroke was found. Additionally, high prevalences of autoimmune disease, hypertension, and thyroid disease were found in our cohort, suggesting that they may play a role in the pathophysiology and progression of moyamoya disease in this population. A new classification for moyamoya is proposed based on these data.

KEY WORDS: Bypass, Moyamoya, Risk factors, White

Neurosurgery 73:984–992, 2013 DOI: 10.1227/NEU.0000000000000162 www.neurosurgery-online.com

Moyamoya disease is a rare cerebrovascular disease characterized by idiopathic stenosis or occlusion of the terminal internal carotid, anterior cerebral, or middle cerebral artery bilaterally with the presence of collateral abnormal vascular networks.[1] Takeuchi and Shimizu[2] are credited with first describing the disease, and Suzuki and Takaku[3] further expanded on the angiographic progression of the disease. Cases with angiographic findings similar to moyamoya but with unilateral disease or associated conditions (Down syndrome, neurofibromatosis type 1, etc) have been called moyamoya syndrome. The vast majority of surgical series have been confined to moyamoya disease in Asian populations[4-6] because they have a higher prevalence compared with whites and African Americans.[7] There is also a moderate number of surgical series evaluating outcomes in pediatric populations.[8-13] Few studies, however, have been conducted on a North American population[14-17]; therefore, less is known about the disease features and outcomes in this population. We present our experience in a North American cohort of patients with moyamoya disease comprising white and African American adults.

ABBREVIATIONS: MCA, middle cerebral artery; **STA,** superficial temporal artery

PATIENTS AND METHODS

Selection Criteria

Under Institutional Review Board approval, institutional databases were searched for patients who

Copyright © Congress of Neurological Surgeons. Unauthorized reproduction of this article is prohibited.

underwent revascularization procedures for moyamoya disease at the Mayo Clinic Rochester and Mayo Clinic Florida. A total of 75 non-Asian patients undergoing 110 procedures were identified between 1979 and 2011. Confirmation of the correct diagnosis was performed by critical review of the angiogram reports or the studies when available. The patients included in this study had angiograms depicting either unilateral or bilateral typical moyamoya changes, including paraclinoid carotid stenosis extending to the M1 segment, proliferation of lenticulostriate arteries, and other collateralization through the posterior circulation.

Baseline Demographics and Outcomes

Baseline clinical data included race, age at presentation, presenting symptoms, and angiographic findings (location and laterality of involved arteries). Comorbidities were also analyzed, including known associations with moyamoya, cerebrovascular risk factors, and autoimmune disease. The primary outcome assessed was a ≥ 30-day event rate, defined as an ischemic stroke or hemorrhage occurring at ≥ 30 days after surgery. Secondary outcomes included perioperative events (ischemic stroke or transient ischemic attacks, hemorrhage) and complications (wound infection, mortality). The majority of patients underwent subsequent clinical follow-up and imaging at 6 months to a year (magnetic resonance angiography or cerebral angiography at 1 year) after the last revascularization procedure to evaluate graft patency. Follow-up thereafter was at the discretion of the operating surgeon or cerebrovascular neurologists. Charts were reviewed until the last contact. Extended follow-up and efforts to obtain additional secondary outcomes were gathered with a standardized follow-up questionnaire based in part on modified Rankin criteria.[18] Attempts were made to contact all patients, who were allowed to respond by either phone or mail. Patients were asked to subjectively rate their quality of life on a 7-point scale, with 7 being rated as very good and 1 as very bad. Patients were also asked about employment and disability status, their ability to ambulate and perform activities of daily living without assistance, whether they were able to drive, if they returned to normal activities after surgery, and whether their disease affected their relationship with family or friends. In addition, patients were asked if they had any further symptoms to extend follow-up in assessing ≥ 30-day event rates.

Surgical Techniques

After induction of general anesthesia, the superficial temporal artery (STA) is mapped with Doppler ultrasound (anterior and posterior divisions). The larger of the 2 divisions based on a preoperative angiogram is then dissected free under the operative microscope. Once adequate length is obtained, the STA is irrigated with heparin and papaverine. The temporalis muscle is incised in a T and reflected inferiorly for a future encephalomyosynangiosis. A circular craniotomy is performed. Under the operative microscope, the dura is opened in cruciate, and the leaflets are cauterized inverted under the bone edges. Multiple incisions are made in the arachnoid. Once an adequate donor artery is chosen, the artery is occluded with 2 number 4 wire clips. The artery is incised. The STA is anastomosed to the middle cerebral artery (MCA) donor branch with multiple interrupted 9-0 monofilament sutures. Doppler is performed to confirm patency of the anastomosis. In 32 patients, anastomotic flow was also determined with a Charbel microflow probe (Transonic Systems, Inc). The temporalis muscle is sewn to the dura with running 4-0 Prolene sutures. The inferior portion of the bone flap is partially rongeured off to allow passage of the STA and muscle and then secured to the skull with the temporalis muscle underneath the bone flap. The wound is then closed in remaining anatomic layers. In 10 patients with unacceptably small donor arteries, an indirect arteriomyoduralsynangiosis was performed.

Statistical Analysis

All statistical analyses were performed with JMP 9.0.1 software. Baseline characteristics were compared among whites and African Americans with the Fisher exact test. Kaplan-Meier curves were used to estimate 5- and 10-year event rates. Each procedure was analyzed independently. Event-free intervals were measured from the time of surgery to either the last contact or date of vascular event. Log-rank statistics were used to assess differences in event rates between procedure types (combined, direct, and indirect). Fisher exact methods were used to assess significant associations with recurrent stroke.

RESULTS

Demographics

A total of 75 non-Asian patients undergoing 110 procedures were included. Baseline characteristics and the type of procedures performed are summarized in Tables 1 and 2. The majority of the procedures performed combined direct and indirect revascularization techniques (n = 88). The mean age of our patient cohort was 42 ± 15 years (range, 18-85 years). The majority of patients treated were female (n = 57). Mean follow-up time after surgery was 47 months (median, 22.5 months; maximum, 427 months). Seventy-one of the 75 patients were white, and 4 were African

TABLE 1. Baseline Characteristics in 75 Patients Undergoing Revascularization for Moyamoya Disease[a]

Characteristic	n (%) (n = 75)
Sex	
Male	18 (24)
Female	57 (76)
Age, y	42 ± 15
Laterality	
Unilateral	26 (35)
Bilateral	49 (65)
Presenting symptoms	
Transient ischemic attack	26 (35)
Hemorrhage	8 (11)
Ischemic stroke	46 (61)
Headache	18 (24)
Cognitive/memory	7 (9)
Cerebrovascular accident risk factors	
Hyperlipidemia	10 (13)
Smoking	13 (17)
Hypertension	9 (12)
Diabetes mellitus	12 (16)
Prior radiation	2 (2.7)
Thyroid disease	6 (8.0)
Autoimmune disease	9 (12)
Recurrent stroke	4 (5)

[a]Group comparisons were made between African Americans and whites, and no significant differences were found with the Fisher Exact Test.

Copyright © Congress of Neurological Surgeons. Unauthorized reproduction of this article is prohibited.

TABLE 2. Type of Surgery in 75 Patients Undergoing 110 Revascularization Procedures

Type of Procedure	n (%)
Direct	12 (11)
Indirect	10 (9)
Combined	88 (80)

American. No baseline differences were noted between whites and African Americans. Most of the cohort had bilateral disease (n = 49) compared with unilateral disease (n = 26). Disease was isolated to the internal carotid artery in 13% (n = 10), was seen in the internal carotid artery with MCA involvement in 13% (n = 10), and involved > 3 arterial territories in 74% (n = 55). All patients were symptomatic, with the most common presenting symptoms being ischemic stroke (n = 46), followed by transient ischemic attacks (n = 26) and hemorrhage (n = 8). Other less common presenting symptoms included headache and cognitive decline or memory loss. A moderate portion of the cohort (44%) had cerebrovascular risk factors, including hyperlipidemia (n = 10), hypertension (n = 9), diabetes mellitus (n = 12), a history of smoking (n = 13), or prior radiation (n = 2). Only 3 patients had known associations with moyamoya syndrome, which included Down syndrome, neurofibromatosis type 1, and fibromuscular dysplasia. Two patients had a history of head trauma. Interestingly, 15% (n = 11) had a history of autoimmune disease or hypothyroidism. The prevalence of cerebrovascular risk factors in comparison to the US population is shown in Table 3.[19-21]

Complications

Perioperative ischemic events occurred in 5 patients (4.5%). Of these, 1 patient experienced a transient ischemic attack. Three experienced minor ischemic strokes, 1 of which occurred contralateral to the operated hemisphere in a patient with bilateral disease. Fortunately, the strokes were minor and did not adversely affect functional recovery at follow-up. Two patients experienced hyperperfusion syndrome after bypass without permanent deficits. There were no intraparenchymal hemorrhages. Two patients had subdural hematomas from the muscle grafts that required evacuation without deficits. There was 1 perioperative death secondary to a pulmonary embolus. Three patients developed ischemic wound edges that required debridement and closure.

TABLE 3. Prevalence of Cerebrovascular Risk Factors Compared With the US Population

Cerebrovascular Risk Factor	Patients, n (%)	Prevalence in General US Population, %
Hyperlipidemia	10 (13)	16.3[19]
Hypertension	9 (12)	24.7[21]
History of smoking	13 (17)	19.3[21]
Diabetes mellitus types 1 and 2	12 (16)	7.9[20]

Intraoperative Blood Flow Measurements and Graft Patency

Although intraoperative patency was confirmed with Doppler in all direct and combined cases when available, anastomotic cerebral blood flow via the Charbel probe was available in only 32 cases. Mean anastomotic flow in these select individuals was 26.4 ± 17.5 mL/min and was highly variable (range, 5-90 mL/min; median, 24 mL/min). Angiographic follow-up data were available in 91 of the 100 combined and direct procedures (example shown in Figure 1). Bypass patency was confirmed in 88 of the 91 cases (97%). The remaining 3 patients had delayed occlusions without symptoms and had developed collaterals in the interim.

Outcomes/Predictors

Events occurring > 30 days from surgery occurred in a total of 4 patients (3.6%). Of these 4 patients, 2 patients had hemorrhages, 1 had a transient ischemic attack, and 1 had a contralateral stroke. The 5- and 10-year event rates via Kaplan-Meier curves were 5.8% and 9.9%, respectively (Figure 2). Log-rank statistics revealed no differences in event-free survival with respect to techniques (P = .55). A significant association was found with a history of thyroid disease and recurrent stroke (P = .05) with the Fisher exact methods. There were positive trends with preoperative hypertension (P = .07) and autoimmune disease (P = .06), although they did not reach statistical significance.

Quality of Life

Quality-of- life data were available in 19 patients via follow-up questionnaires (25% response rate). The median follow-up in this subset of patients was 94 months. The average subjective quality-of-life rating was 5.6 on a 7-point scale (7 being very good). The employment rate was 53%. Nearly half (47%) of patients reported being disabled, although 95% maintained the ability to drive. All were able to ambulate independently. The majority (74%) were independent in activities of daily living and were able to resume the same activity level before surgery (modified Rankin Scale score, 0-1).

DISCUSSION

The Natural History and Surgery

The natural history of typical moyamoya has previously been outlined in a number of series and generally is poor.[22-25] Kuroda et al[23] studied 86 hemispheres in 63 patients and found a progression rate of 17.4% per hemisphere and of 23.8% per patient. A large portion with unilateral disease (38.9% per Kelly et al[22]) will eventually develop bilateral disease. The stroke rate in asymptomatic patients is 3.2%/y.[26] Once a patient has become symptomatic, the risk of recurrent stroke is much higher, with the reported range in the literature being 10.3% per year[24] to 16% per year or 80.95% at 5 years.[25] Indirect and direct bypass

Copyright © Congress of Neurological Surgeons. Unauthorized reproduction of this article is prohibited.

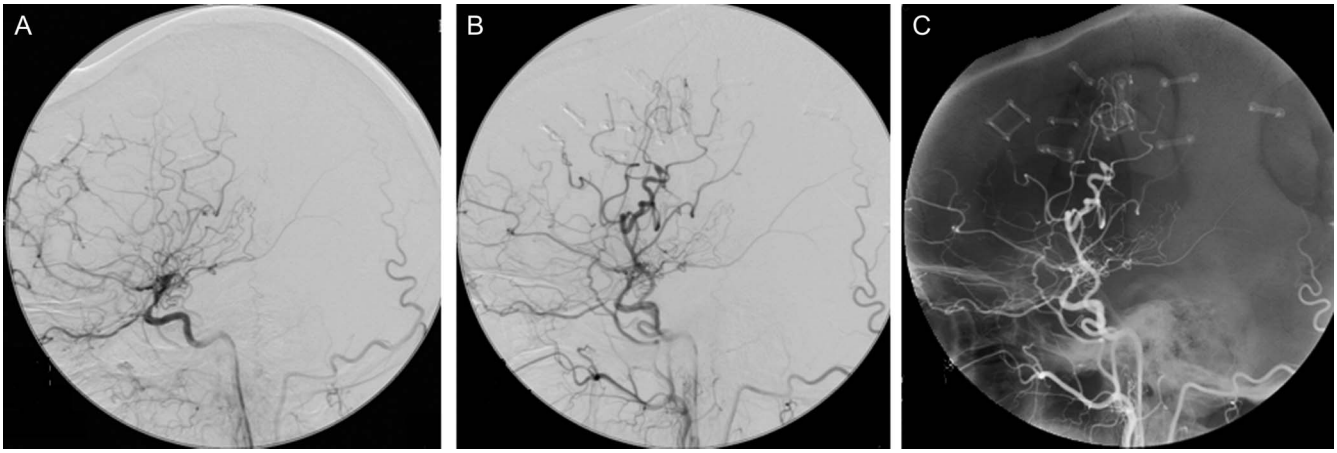

FIGURE 1. *Preoperative and postoperative angiograms of a 48-year-old woman with primary biliary cirrhosis and hypothyroidism who underwent a left superficial temporal artery-middle cerebral artery bypass. The patient initially presented with a left temporal intraparenchymal hematoma.* **A**, *preoperative lateral common carotid injection.* **B** *and* **C**, *postoperative lateral common carotid injection showing a patent bypass at 1 year.*

techniques have been shown to alter the natural history. Hallemeier et al[16] found that the cumulative stroke risk at 5 years decrease to 17%. Similarly, Kraemer et al[25] reported a reduction to 27% in Europeans, and more recently, Guzman et al[15] noted a reduction to 5.6% at 5 years in a North American population. Our results are nearly identical; our 5- and 10-year cumulative stroke rates were 5.8% and 9.9%.

Limitations

Although the overall low event rate (n = 4) in the present series is consistent with previous studies, there is a potential limitation in assuming independence in patients undergoing bilateral procedures. If a first-time revascularization lowers the contralateral stroke risk, evaluating each procedure independently could underestimate cumulative stroke rates. Nonetheless, our results and existing literature suggest that symptomatic patients benefit from revascularization. Whether asymptomatic patients also benefit from revascularization remains to be determined, although the relatively low perioperative risk (4.5%) compared with the natural history (3.2%/y stroke risk) suggests that they may also benefit as well.

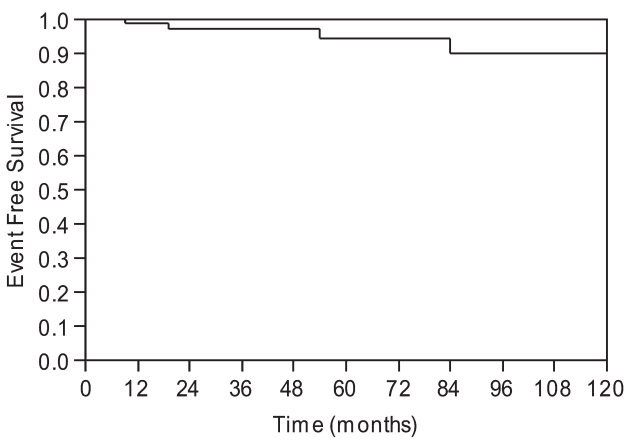

FIGURE 2. *Event-free survival. Kaplan-Meier methods estimated the cumulative risk of ≥ 30-day event rates to be 95% at 5 years and 90% at 10 years.*

Quality of Life

Although we had a limited number of quality-of-life surveys, this information indicates that in addition to lowering risk of recurrent stroke, revascularization positively affects quality of life. After surgery, more than half of the patients were able to return to work. The majority of patients were able to drive, and approximately 70% were able to resume normal activities and to maintain independence in activities of daily living. Few studies have directly examined quality of life after surgery, although they also have found improvement in quality of life. Guzman et al[15] found significant improvement in quality of life as measured by the modified Rankin Scale score. An earlier series by Choi et al[27] found significant improvement in activities of daily living in surgically treated patients (55% vs 26%).

Risk Factors for Recurrent Stroke

Interestingly, we found significant correlations with risk of recurrent stroke after revascularization with a history of thyroid disease (hypothyroidism and hyperthyroidism) and positive trends with autoimmune disease and hypertension. The significance of the correlations is unclear. Foremost, because they are based on a relatively small number of patients, they should be interpreted with caution because there is a possibility that the positive trends reflect sampling error. However, the following suggests that thyroid disease, autoimmune disease, and hypertension may play a role in the pathophysiology of the disease. First, one of the 4

Copyright © Congress of Neurological Surgeons. Unauthorized reproduction of this article is prohibited.

TABLE 4. New Proposed Classification for Moyamoya Based on Etiology[a]

Type	Description
I	Classic moyamoya associated with primary genetic abnormalities in Asians (ie, rnf213 gene,[40,45] mmp3 gene[46])
II	Moyamoya associated with other genetic syndromes or susceptibility genes in whites (ie NF-1,[51] HLA-DRB1*03,[50] tgfb1 gene[50])
III	Moyamoya associated with autoimmune disorders (ie, Graves disease[53])
IV	Moyamoya associated with atherosclerosis/vasculitis

[a]mmp3- matrix metalloproteinase; NF-1, neurofibromatosis type 1; rnf213, ring finger protein 213; tgfb1, transforming growth factor-β1.

strokes observed was contralateral, which implicates continued progression as the cause of the delayed stroke. In addition, there was a surprisingly high incidence of both a history of autoimmune disease or thyroid disease (15%) and hypertension (12%) among our cohort. Of the 6 patients with thyroid disorders, 5 had primary hypothyroidism: 1 had Hashimoto hypothyroidism and the other 4 had primary hypothyroidism without further delineated types. The other patient initially had Graves disease but was secondarily hypothyroid after treatment. Interestingly, 3 of the 6 patients had other autoimmune-mediated diseases (diabetes mellitus type 1 and primary biliary cirrhosis). Graves disease, a known autoimmune-mediated thyroid disease, has previously been described in association with moyamoya syndrome.[28,29] Furthermore, the presence of thyroid autoantibodies has been associated with the development of moyamoya.[30,31] Hypertension, on the other hand, may be a secondary phenomenon. Renovascular stenosis has been shown to occur in 5% of patients with moyamoya, suggesting that some patients may have renal artery involvement.[32]

Postoperative Hyperperfusion Syndrome

Another distinguishing feature of the select cohort from prior Asian and pediatric series appears to be a lower incidence of postoperative hyperfusion syndrome. In Asian populations, the incidence reported in the literature ranges from 6.7% to 50%, depending on the definition (radiographic vs symptomatic) and method of study,[33-37] with recent studies suggesting the rate of symptomatic hyperfusion to be about 20% to 30%.[36,38] Only 2 patients (1.8%) in the present series developed symptomatic hyperfusion after bypass. Similarly, Guzman et al[15] noted transient neurological deficits in only 3.3% of their North American cohort (n = 450). Reasons for the lower incidence are not entirely clear. Previously cited risk factors for hyperperfusion in Asian cohorts include increased preoperative cerebral blood volume,[37] intraoperative cerebral blood flow,[35] perioperative blood pressure,[33] and adult and hemorrhagic onset as presenting features.[36] Notably, the present and previously published North American series[15-17] show that hemorrhage is less common at initial presentation in this subset. If hemorrhagic presentation is a risk factor, it may partially explain the finding of a lower postoperative rate of hyperfusion. The other aforementioned risk factors have not been well studied in non-Asian moyamoya populations as they relate to the development of hyperperfusion. We suspect that differences in anastomotic flow, however, may also be contributory. Okada et al[6] studied anastomotic flow in 15 moyamoya patients after STA-MCA bypass who presented with ischemia and found the mean anastomotic flow to be 34.1 mL/min compared with 26.4 mL/min in the present series. Interestingly, Lee et al[39] found that the higher anastomotic flows after STA-MCA bypass in 292 patients correlated with postoperative stroke, hemorrhage, and transient neurological deficits. Because anastomotic flow was not available in a large part of our cohort, no firm conclusions can be made owing to the high potential for selection bias.

Proposed Classification System

There is confusion in the neurosurgery literature as to what is meant by moyamoya disease. When considering the specific genotype of an Asian population with bilateral angiographic findings, all surgeons would agree with use of the term moyamoya disease. With other genotypes like Down syndrome or neurofibromatosis, terms including moyamoya disease, moyamoya syndrome, secondary moyamoya, or moyamoya phenomenon are used interchangeably. This study indicates that autoimmune disease is yet another potential type of this disease because the angiograms are interchangeable with those with classic moyamoya disease. Hence, it would be reasonable to codify all genotype-associated moyamoya patients as moyamoya disease and to assign the term moyamoya syndrome to patients with unilateral or bilateral disease with an origin associated with autoimmune, vascular risk factors, or as-yet identified reasons. Another classification option to further avoid confusion and to help researchers identify etiologies and direct treatments would be to classify moyamoya on a genetic and etiological basis (Table 4). Genetic causes have been implicated primarily in Asian patients[40-47] and, to lesser extent, in white populations and genetic syndromes (ie, Down syndrome and neurofibromatosis).[48-52] These could be designated moyamoya type 1 (Asian genotype) and moyamoya type 2 (white genotype and other genetic syndromes). Furthermore, autoimmune disorders[30,53-59] and atherosclerosis/vasculitis[60-66] have been associated with the moyamoya phenotype and could be designated moyamoya type 3 and 4, respectively. Figure 3 shows select examples.

CONCLUSION

We report favorable results with direct and indirect revascularization for moyamoya in an understudied adult population. The 5- and

Copyright © Congress of Neurological Surgeons. Unauthorized reproduction of this article is prohibited.

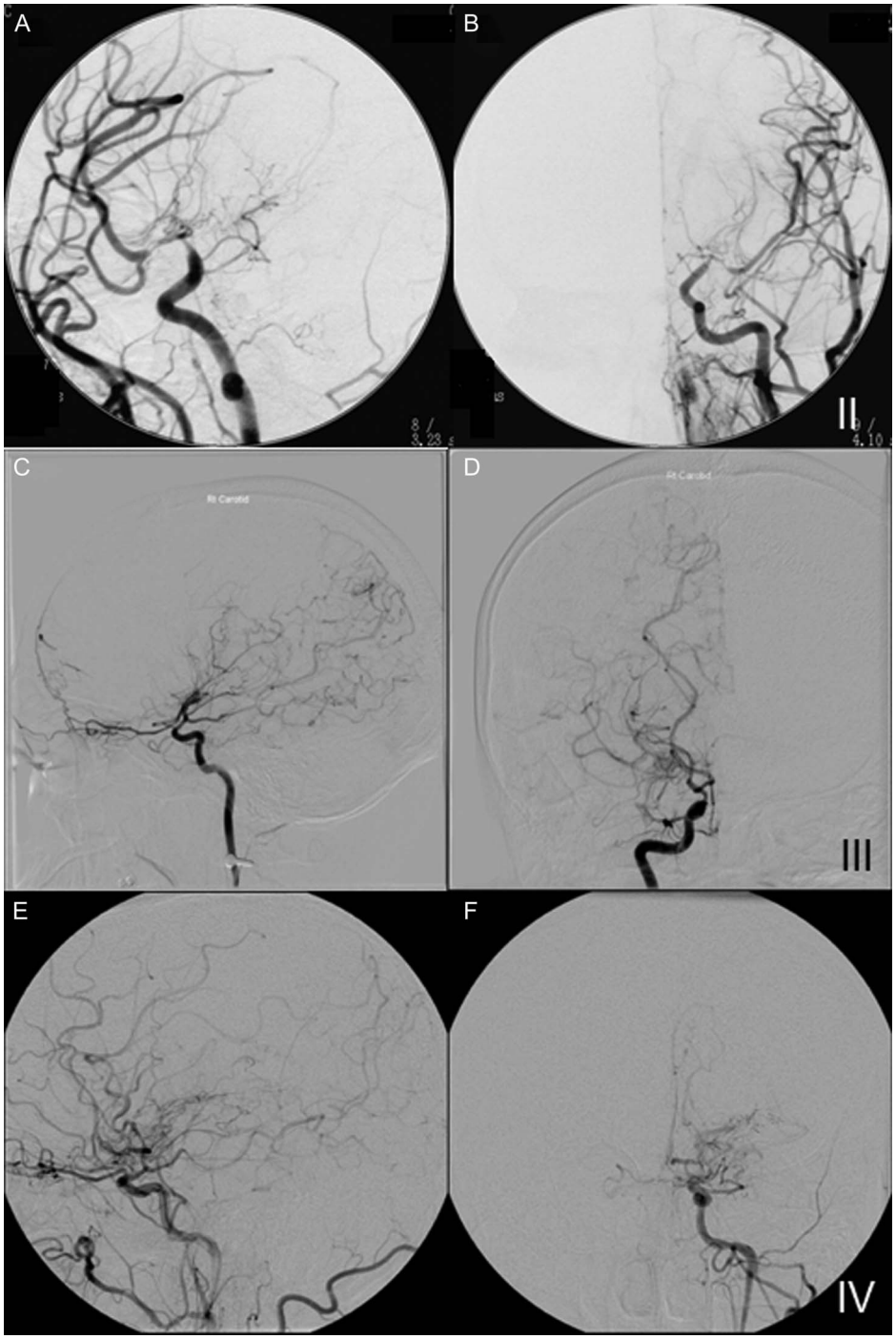

FIGURE 3. *Select angiograms demonstrating moyamoya types II through IV. Type II: lateral and anteroposterior common carotid injections (**A** and **B**) in a 26-year-old patient with Down syndrome presenting with a left hemispheric ischemic stroke. Type III: lateral and anteroposterior internal carotid injections (**C** and **D**) in a 19-year-old patient with primary hypothyroidism and autoimmune diabetes mellitus type I presenting with right hemispheric transient ischemic attacks. Type IV: lateral and anteroposterior common carotid injections (**E** and **F**) in a 57-year-old man with hypertension presenting with left hemispheric transient ischemic attacks.*

Copyright © Congress of Neurological Surgeons. Unauthorized reproduction of this article is prohibited.

10-year cumulative risks of stroke were 5.8% and 9.9%. Perioperative stroke risk was 4.5%. Trends were found with recurrent stroke and a history of thyroid disease, hypertension, and autoimmune disease, which suggests that they may play a role in the pathophysiology and disease progression of moyamoya in this subset of patients.

Disclosure

The authors have no personal financial or institutional interest in any of the drugs, materials, or devices described in this article.

REFERENCES

1. Fukui M. Guidelines for the diagnosis and treatment of spontaneous occlusion of the circle of Willis ("moyamoya" disease): Research Committee on Spontaneous Occlusion of the Circle of Willis (Moyamoya Disease) of the Ministry of Health and Welfare, Japan. *Clin Neurol Neurosurg.* 1997;99(suppl 2): S238-S240.
2. Takeuchi K, Shimizu K. Hypoplasia of the bilateral internal carotid arteries. *Brain Nerve*. 1957;9:37-43.
3. Suzuki J, Takaku A. Cerebrovascular "moyamoya" disease: disease showing abnormal net-like vessels in base of brain. *Arch Neurol.* 1969;20(3):288-299.
4. Fukui M. Current state of study on moyamoya disease in Japan. *Surg Neurol.* 1997;47(2):138-143.
5. Yoshida Y, Yoshimoto T, Shirane R, Sakurai Y. Clinical course, surgical management, and long-term outcome of moyamoya patients with rebleeding after an episode of intracerebral hemorrhage: an extensive follow-up study. *Stroke*. 1999;30(11):2272-2276.
6. Okada Y, Shima T, Nishida M, Yamane K, Yamada T, Yamanaka C. Effectiveness of superficial temporal artery-middle cerebral artery anastomosis in adult moyamoya disease: cerebral hemodynamics and clinical course in ischemic and hemorrhagic varieties. *Stroke*. 1998;29(3):625-630.
7. Uchino K, Johnston SC, Becker KJ, Tirschwell DL. Moyamoya disease in Washington State and California. *Neurology*. 2005;65(6):956-958.
8. Olds MV, Griebel RW, Hoffman HJ, Craven M, Chuang S, Schutz H. The surgical treatment of childhood moyamoya disease. *J Neurosurg.* 1987;66(5): 675-680.
9. Golby AJ, Marks MP, Thompson RC, Steinberg GK. Direct and combined revascularization in pediatric moyamoya disease. *Neurosurgery*. 1999;45(1):50-58; discussion 58-60.
10. Kim SK, Wang KC, Kim DG, et al. Clinical feature and outcome of pediatric cerebrovascular disease: a neurosurgical series. *Childs Nerv Syst.* 2000;16(7): 421-428.
11. Scott RM, Smith JL, Robertson RL, Madsen JR, Soriano SG, Rockoff MA. Long-term outcome in children with moyamoya syndrome after cranial revascularization by pial synangiosis. *J Neurosurg.* 2004;100(2 Suppl Pediatrics):142-149.
12. Nissim O, Bakon M, Ben Zeev B, et al. Moyamoya disease: diagnosis and treatment: indirect cerebral revascularization at the Sheba Medical Center. *Isr Med Assoc J.* 2005;7(10):661-666.
13. Turhan T, Ersahin Y. Indirect bypass procedures for moyamoya disease in pediatric patients. *Turkish Neurosurg.* 2011;21(2):160-166.
14. Mesiwala AH, Sviri G, Fatemi N, Britz GW, Newell DW. Long-term outcome of superficial temporal artery-middle cerebral artery bypass for patients with moyamoya disease in the US. *Neurosurg Focus.* 2008;24(2):E15.
15. Guzman R, Lee M, Achrol A, et al. Clinical outcome after 450 revascularization procedures for moyamoya disease: clinical article. *J Neurosurg.* 2009;111(5): 927-935.
16. Hallemeier CL, Rich KM, Grubb RL Jr, et al. Clinical features and outcome in North American adults with moyamoya phenomenon. *Stroke*. 2006;37(6): 1490-1496.
17. Wetjen NM, Garell PC, Stence NV, Loftus CM. Moyamoya disease in the midwestern United States. *Neurosurg Focus.* 1998;5(5):5e1.
18. United Kingdom Transient Ischaemic Attack (UK-TIA) Aspirin Trial. Interim results: UK-TIA Study Group. *Br Med J (Clin Res Ed).* 1988;296(6618):316-320.
19. Cholesterol fact sheet Division for Heart disease and Stroke Prevention. Atlanta, Ga: Centers for Disease Control and Prevention.
20. National Diabetes Statistics. National Diabetes Information Clearinghouse (NDIC), a service of the National Institute of Diabetes and Digestive and Kidney Diseases (NIDDK), National Institutes of Health. 2011.
21. Summary Health Statistics for US Adults: national health interview survey, 2010. Vital and health statistics, series 10, number 252, January 2012; Centers for disease control and Prevention.
22. Kelly ME, Bell-Stephens TE, Marks MP, Do HM, Steinberg GK. Progression of unilateral moyamoya disease: a clinical series. *Cerebrovasc Dis.* 2006;22(2-3): 109-115.
23. Kuroda S, Ishikawa T, Houkin K, Nanba R, Hokari M, Iwasaki Y. Incidence and clinical features of disease progression in adult moyamoya disease. *Stroke*. 2005;36 (10):2148-2153.
24. Chiu D, Shedden P, Bratina P, Grotta JC. Clinical features of moyamoya disease in the United States. *Stroke*. 1998;29(7):1347-1351.
25. Kraemer M, Heienbrok W, Berlit P. Moyamoya disease in Europeans. *Stroke*. 2008;39(12):3193-3200.
26. Kuroda S, Hashimoto N, Yoshimoto T, Iwasaki Y. Radiological findings, clinical course, and outcome in asymptomatic moyamoya disease: results of multicenter survey in Japan. *Stroke*. 2007;38(5):1430-1435.
27. Choi JU, Kim DS, Kim EY, Lee KC. Natural history of moyamoya disease: comparison of activity of daily living in surgery and non surgery groups. *Clin Neurol Neurosurg.* 1997;99(suppl 2):S11-S18.
28. Ohba S, Nakagawa T, Murakami H. Concurrent Graves' disease and intracranial arterial stenosis/occlusion: special considerations regarding the state of thyroid function, etiology, and treatment. *Neurosurg Rev.* 2011;34:297-304; discussion 304.
29. Im SH, Oh CW, Kwon OK, Kim JE, Han DH. Moyamoya disease associated with Graves disease: special considerations regarding clinical significance and management. *J Neurosurg.* 2005;102(6):1013-1017.
30. Kim SJ, Heo KG, Shin HY, et al. Association of thyroid autoantibodies with moyamoya-type cerebrovascular disease: a prospective study. *Stroke*. 2010;41(1): 173-176.
31. Li H, Zhang ZS, Dong ZN, et al. Increased thyroid function and elevated thyroid autoantibodies in pediatric patients with moyamoya disease: a case-control study. *Stroke*. 2011;42(4):1138-1139.
32. Togao O, Mihara F, Yoshiura T, et al. Prevalence of stenoocclusive lesions in the renal and abdominal arteries in moyamoya disease. *AJR Am J Roentgenol.* 2004;183 (1):119-122.
33. Fujimura M, Inoue T, Shimizu H, Saito A, Mugikura S, Tominaga T. Efficacy of prophylactic blood pressure lowering according to a standardized post-operative management protocol to prevent symptomatic cerebral hyperperfusion after direct revascularization surgery for moyamoya disease. *Cerebrovasc Dis.* 2012;33(5):436-445.
34. Fujimura M, Kaneta T, Mugikura S, Shimizu H, Tominaga T. Temporary neurologic deterioration due to cerebral hyperperfusion after superficial temporal artery-middle cerebral artery anastomosis in patients with adult-onset moyamoya disease. *Surg Neurol.* 2007;67(3):273-282.
35. Kawamata T, Kawashima A, Yamaguchi K, Hori T, Okada Y. Usefulness of intraoperative laser Doppler flowmetry and thermography to predict a risk of postoperative hyperperfusion after superficial temporal artery-middle cerebral artery bypass for moyamoya disease. *Neurosurg Rev.* 2011;34(3):355-362; discussion 362.
36. Fujimura M, Mugikura S, Kaneta T, Shimizu H, Tominaga T. Incidence and risk factors for symptomatic cerebral hyperperfusion after superficial temporal artery-middle cerebral artery anastomosis in patients with moyamoya disease. *Surg Neurol.* 2009;71(4):442-447.
37. Uchino H, Kuroda S, Hirata K, Shiga T, Houkin K, Tamaki N. Predictors and clinical features of postoperative hyperperfusion after surgical revascularization for moyamoya disease: a serial single photon emission CT/positron emission tomography study. *Stroke*. 2012;43(10):2610-2616.
38. Fujimura M, Shimizu H, Inoue T, Mugikura S, Saito A, Tominaga T. Significance of focal cerebral hyperperfusion as a cause of transient neurologic deterioration after extracranial-intracranial bypass for moyamoya disease: comparative study with non-moyamoya patients using n-isopropyl-p-[(123)i]iodoamphetamine single-photon emission computed tomography. *Neurosurgery*. 2011;68(4):957-964; discussion 964-965.

Copyright © Congress of Neurological Surgeons. Unauthorized reproduction of this article is prohibited.

39. Lee M, Guzman R, Bell-Stephens T, Steinberg GK. Intraoperative blood flow analysis of direct revascularization procedures in patients with moyamoya disease. *J Cereb Blood Flow Metab.* 2011;31(1):262-274.
40. Wu Z, Jiang H, Zhang L, et al. Molecular analysis of rnf213 gene for moyamoya disease in the Chinese Han population. *PLoS One*. 2012;7(10):e48179.
41. Park YS, Jeon YJ, Lee BE, et al. Association of the mir-146ac>g, mir-196a2c>t, and mir-499a>g polymorphisms with moyamoya disease in the Korean population. *Neurosci Lett.* 2012;521(1):71-75.
42. Miyawaki S, Imai H, Takayanagi S, Mukasa A, Nakatomi H, Saito N. Identification of a genetic variant common to moyamoya disease and intracranial major artery stenosis/occlusion. *Stroke*. 2012;43(12):3371-3374.
43. Liu W, Morito D, Takashima S, et al. Identification of rnf213 as a susceptibility gene for moyamoya disease and its possible role in vascular development. *PLoS One*. 2011;6(7):e22542.
44. Park YS, Min KT, Kim TG, et al. Age-specific eNOS polymorphisms in moyamoya disease. *Childs Nerv Syst.* 2011;27(11):1919-1926.
45. Kamada F, Aoki Y, Narisawa A, et al. A genome-wide association study identifies rnf213 as the first Moyamoya disease gene. *J Hum Genet.* 2011;56(1):34-40.
46. Li H, Zhang ZS, Liu W, et al. Association of a functional polymorphism in the mmp-3 gene with moyamoya disease in the Chinese Han population. *Cerebrovasc Dis.* 2010;30(6):618-625.
47. Graham JF, Matoba A. A survey of moyamoya disease in Hawaii. *Clin Neurol Neurosurg.* 1997;99(suppl 2):S31-S35.
48. Kraemer M, Horn PA, Roder C, et al. Analysis of human leucocyte antigen genes in white patients with idiopathic moyamoya angiopathy. *Acta Neurochir (Wien).* 2012;154(3):445-454.
49. Andreone V, Ciarmiello A, Fusco C, Ambrosanio G, Florio C, Linfante I. Moyamoya disease in Italian monozygotic twins. *Neurology.* 1999;53(6):1332-1335.
50. Roder C, Peters V, Kasuya H, et al. Polymorphisms in TGFB1 and PDGFRB are associated with moyamoya disease in European patients. *Acta Neurochir (Wien).* 2010;152(12):2153-2160.
51. Koc F, Yerdelen D, Koc Z. Neurofibromatosis type 1 association with moyamoya disease. *Int J Neurosci.* 2008;118(8):1157-1163.
52. Ullrich NJ, Koss M, Scott RM, Smith ER, Ullrich NJ. Moyamoya syndrome associated with neurofibromatosis type 1 in children: perioperative and long-term outcome after pial synangiosis. *Neurosurgery*. 2012;71(4):E566.
53. Suzuki S, Mitsuyama T, Horiba A, Fukushima S, Hashimoto N, Kawamata T. Moyamoya disease complicated by Graves' disease and type 2 diabetes mellitus: report of two cases. *Clin Neurol Neurosurg.* 2011;113(4):325-329.
54. Prelipcean V, Koch AE. Systemic lupus erythematosus associated with moyamoya disease case report and review of the literature. *J Clin Rheumatol.* 1998;4(6):328-332.
55. Leno C, Mateo I, Cid C, Berciano J, Sedano C. Autoimmunity in Down's syndrome: another possible mechanism of moyamoya disease. *Stroke*. 1998;29(4): 868-869.
56. Tendler BE, Shoukri K, Malchoff C, et al. Concurrence of Graves' disease and dysplastic cerebral blood vessels of the moyamoya variety. *Thyroid*. 1997;7(4):625-629.
57. Wanifuchi H, Kagawa M, Takeshita M, Izawa M, Maruyama S, Kitamura K. Autoimmune antibody in moyamoya disease [in Japanese]. *No Shinkei Geka.* 1986;14(1):31-35.
58. Bower RS, Mallory GW, Nwojo M, Meyer FB, Kudva YC. Diabetes mellitus and the moyamoya syndrome. *Ann Intern Med.* 2012;157(5):387-388.
59. Ogawa K, Nagahiro S, Arakaki R, Ishimaru N, Kobayashi M, Hayashi Y. Anti-alpha-fodrin autoantibodies in moyamoya disease. *Stroke*. 2003;34(12):e244-e246.
60. Bower RS, Mallory GW, Nwojo M, Kudva YC, Flemming KD, Meyer FB. Moyamoya disease in a primarily white, midwestern US population: increased prevalence of autoimmune disease. *Stroke*. 2013;44(7):1997-1999.
61. Ogata T, Yasaka M, Inoue T, et al. The clinical features of adult unilateral moyamoya disease: does it have the same clinical characteristics as typical moyamoya disease? *Cerebrovasc Dis.* 2008;26(3):244-249.
62. Kato H, Shimosegawa E, Oku N, et al. Cerebral hemodynamics and oxygen metabolism in patients with moyamoya syndrome associated with atherosclerotic steno-occlusive arterial lesions. *Cerebrovasc Dis.* 2008;26(1):9-15.
63. Roder C, Peters V, Kasuya H, et al. Common genetic polymorphisms in moyamoya and atherosclerotic disease in Europeans. *Childs Nerv Syst.* 2011;27(2): 245-252.
64. Tanaka M, Sakaguchi M, Kitagawa K. Mechanism of moyamoya vessels secondary to intracranial atherosclerotic disease: angiographic findings in patients with middle cerebral artery occlusion. *J Stroke Cerebrovasc Dis.* 2012;21(5):373-378.
65. Yanagawa Y, Sugiura T, Suzuki K, Okada Y. Moyamoya disease associated with positive findings for rheumatoid factor and myeloperoxidase-anti-neutrophil cytoplasmic antibody. *West Indian Med J.* 2007;56(3):282-284.
66. Skeik N, Rumery KK, Udayakumar PD, Crandall BM, Warrington KJ, Sullivan TM. Concurrent Takayasu arteritis with common variable immunodeficiency and moyamoya disease. *Ann Vasc Surg.* 2013;27(2):240 e213-e248.

COMMENTS

I congratulate the authors on wringing any data or conclusions from this relatively small series of moyamoya patients obtained from the surgical records of the Mayo Clinic over a 32-year period. I found their article interesting and well written. Only 75 "moyamoya" patients were operated on at this tertiary referral center, which is known especially for departmental expertise in vascular neurosurgery—ample evidence of the rarity of this condition in actual practice.

The authors' observations regarding the association of thyroid disease and additional autoimmune disorders such as primary biliary cirrhosis, along with the genetic conditions like Down syndrome and neurofibromatosis, with a moyamoya phenomenon have been confirmed by many previous authors, as the authors note in their Discussion. The authors' proposed classification of moyamoya patients into 4 groups—Asian, genetic, autoimmune, and atherosclerotic—is intriguing.

I have several concerns with their conclusions. The study is woefully underpowered for the conclusions that are made, despite the statistical support they provide. Their follow-up data, with survival tables, are presented as significant, but in the body of the article, it is apparent that there are very few late clinical examinations for follow-up purposes, and only 19 of their 75 patients returned a questionnaire regarding quality of life. The authors describe their surgical technique in detail, but readers will want to see for themselves how effective these combined surgical procedures have been, especially in the 10 patients in whom no suitable donor vessel was found and indirect procedures were required. In fact, none of the postoperative studies that the authors provide show any of the arteriograms from the "combined surgical approach" cases. A few more of the preoperative arteriograms in their most controversial moyamoya group—the atherosclerotic, hypertensive patients—would also be instructive because many of these patients in my opinion have occlusive disease only, with none of the hallmarks of moyamoya disease such as the presence of basal moyamoya vessels and spontaneous transdural collateral.

Many of us do not believe that these patients have moyamoya and would anticipate that their response to a purely indirect procedure, for example, might be suboptimal. It would have been interesting to see how these patients responded to their procedures from an imaging standpoint.

R. Michael Scott
Boston, Massachusetts

The authors reported the surgical outcomes and predictors of stroke in a North American white and African American adult moyamoya populations at the Mayo Clinic. According to their data, they proposed a new classification system of moyamoya patients into 4 groups: Asian genotype, white genotype and other genetic syndrome, autoimmune diseases, and atherosclerosis. This classification system could be useful in perioperative management of moyamoya disease. Stricter blood pressure control is essential for Asian moyamoya patients in light of the high prevalence of hyperperfusion syndrome after revascularization surgery compared with non-Asian moyamoya patients. Controlling autoimmune disease such as thyroid disease leads to the prevention of the exacerbation of moyamoya disease itself. Recently, moyamoya disease has been

Copyright © Congress of Neurological Surgeons. Unauthorized reproduction of this article is prohibited.

analyzed from another genetic viewpoint, and the gene attracting the most attention is RNF213.[1] RNF213 is reported to be related to age at onset or the degree of severity of moyamoya disease.[2] We hope that the authors will investigate the correlation between RNF 213 and the factors of classification proposed in the next stage.

Tomohito Hishikawa, Isao Date
Okayama, Japan

1. Liu W, Morito D, Takashima S, et al. Identification of RNF213 as a susceptibility gene for moyamoya disease and its possible role in vascular development. *PLoS One*. 2011;6(7):e22542.
2. Miyatake S, Miyake N, Touho H, et al. Homozygous c. 14576G>A variant of RNF213 predicts early-onset and severe form of moyamoya disease. *Neurology*. 2012;78(11):803-810.

The authors retrospectively reviewed 75 non-Asian moyamoya patients undergoing 110 surgeries at the Mayo Clinic and examined outcomes after revascularization for white and African American adults. Perioperative ischemic events occurred in 5 patients (4.5%), consistent with previous reports. It should be noted, however, that the incidence of hyperperfusion syndrome was as low as 1.8% (2 of 110) in their series, contrary to the relatively high incidence of symptomatic cerebral hyperperfusion among Asian moyamoya patients, ranging from 16.7% to 38.2%. The authors raised the important suggestion that substantial risk of hyperperfusion syndrome after revascularization could be much higher in Asian patients compared with white moyamoya patients, although the underlying pathology is undetermined.

Further understanding of the difference in early perioperative response between Asian and non-Asian patients is essential because the management of ischemia and the management of hyperperfusion are contradictory to each other, and both perioperative infarction and hemorrhagic conversion of hyperperfusion could lead to significant morbidity. Because the susceptibility gene for moyamoya disease, RNF213, was recently identified among Asian patients,[1] comparative genetic analysis between Asian and white patients would be of great interest. Alternatively, comparative evaluation of inflammatory biomarkers, including matrix metalloproteinases,[2,3] that relate to blood-brain barrier maintenance or hemorrhagic conversion may address this important issue.

Miki Fujimura
Sendai, Japan

1. Kamada F, Aoki Y, Narisawa A, et al. A genome-wide association study identifies RNF213 as the first moyamoya disease gene. *J Human Genet.* 2011;56(1):34-40.
2. Kang HS, Kim JH, Phi JH, et al. Plasma matrix metalloproteinases, cytokines and angiogenic factors in moyamoya disease. *J Neurol Neurosurg Psychiatry.* 2010;81(6):673-678.
3. Fujimura M, Watanabe M, Narisawa A, et al. Increased expression of serum matrix metalloproteinase-9 in patients with moyamoya disease. *Surg Neurol.* 2009:72(5):476-480.



Swipe.

The NEUROSURGERY® iPad Application.

Read full issues of *Neurosurgery* and *Operative Neurosurgery* on your iPad, archive or delete downloaded issues, share articles via email or social media, access digital supplemental content, and automatic notification of new issues.

Available for free download via the App Store.

NEUROSURGERY

view with layar

Apple and iPad are trademarks of Apple Inc., registered in the U. S. and other countries. App Store is a service mark of Apple Inc.

Copyright © Congress of Neurological Surgeons. Unauthorized reproduction of this article is prohibited.